

ACUTE POSTPARTUM PULMONARY EDEMA IN A 34-YEAR-OLD PREECLAMPSIA WOMAN

Yohanes Susanto¹, Patrice Ginting², Ruddy Hardiansyah³

¹General Practitioner, Metta Medika Hospital, Sibolga, North Sumatera

²Internist, Metta Medika Hospital, Sibolga, North Sumatera

³Anesthesiologist-Intensivist, Metta Medika Hospital, Sibolga, North Sumatera

ABSTRACT

Acute dyspnea after pregnancy is a rare presentation and a number of important conditions may accompany it. Pulmonary embolism, amniotic fluid embolism, pneumonia, aspiration, and pulmonary edema are some of the potential causes that must be considered. Pulmonary edema complicates around 0,05% of low-risk pregnancies but may develop in up to 2,9% of pregnancies complicated by preeclampsia, with 70% of cases occurring after birth. The most common contributing factors include peripartum cardiomyopathy, underlying cardiac disease, preeclampsia, administration of tocolytic agents and iatrogenic fluid overload. Here we report a case of 34-year-old woman of 1st postpartum day following lower uterine cesarean section presented with acute progressive dyspnea from her first pregnancy who was admitted in intensive care unit with history of preeclampsia. Clinical examination and relevant investigations explored that it was a case of acute pulmonary edema. Patient was kept in ventilator and was treated with intravenous diuretic and calcium channel blocker. After diuresis, considerable improvement was observed in her respiratory status. The day after, the patient became hemodynamically stable and was weaned off the ventilator. After seven days, she was discharged in stable condition.

Keywords: post-partum, pulmonary edema, preeclampsia

ABSTRAK

Dispnea akut setelah kehamilan merupakan keadaan yang jarang terjadi serta seringkali disertai kondisi-kondisi penting lainnya. Emboli paru, emboli air ketuban, pneumonia, aspirasi, dan edema paru, adalah penyebab dispnea yang perlu dipikirkan. Edema paru terjadi pada 0,05% pada kehamilan dengan risiko rendah, tetapi dapat meningkat menjadi sebesar 2,9% pada kehamilan dengan preeklampsia, dengan 70% terjadi setelah persalinan. Faktor pendukung lainnya adalah kardiomiopati peripartum, adanya penyakit jantung, preeklampsia, pemberian obat tokolitik, dan kelebihan pemberian cairan. Berikut ini adalah sebuah kasus pada seorang perempuan berusia 34 tahun post partum 1 hari dengan riwayat sectio caesarea dan preeklampsia yang mengalami dispnea akut progresif sehingga dirawat di ICU. Pemeriksaan fisik dan pemeriksaan lainnya menunjukkan bahwa kasus ini merupakan sebuah kasus edema paru akut. Pasien menggunakan ventilator dan mendapat terapi diuretik intravena serta penyekat kanal kalsium. Setelah mendapat terapi diuresis, kondisi pasien membaik. Setelah tujuh hari perawatan, pasien dipulangkan dengan kondisi stabil

Kata kunci: post-partum, edema paru, eklampsia

Introduction

Postpartum pulmonary edema is a rare clinical entity.¹ Acute pulmonary edema, which signifies severe disease, is a leading cause of death in women with preeclampsia, and the fourth most common form of maternal morbidity. It is also frequently the reason for intensive care admission, and may occur during antenatal, intrapartum or postpartum periods.² Pulmonary edema complicates around 0,05% of low-risk pregnancies but may develop in up to 2,9% of pregnancies complicated by preeclampsia³⁻⁴, with 70% of cases occurring after birth.²⁻³ A clinician needs to be aware of the physiologic changes in the maternal cardiovascular system that accompany pregnancy predispose to the development of pulmonary edema, such as increase in plasma blood volume, cardiac output, heart rate, and capillary permeability and a decrease in plasma colloid osmotic pressure. Resuscitation is the foremost priority, followed by formulation of a differential diagnosis to address the underlying condition.⁴ Here we report a postpartum patient who presented with acute pulmonary edema with severe respiratory compromise.

Case Illustration

The patient was a 34-year-old primigravida woman with preeclampsia who was admitted to the hospital for delivery by cesarean section. Apparently there were no problems with the operative procedure.

Approximately 20 hours later, she presented progressive dyspnea. She looked pale, unwell and was able to speak only a few words. On physical examination, she had marked respiratory distress and chest auscultation revealed basal crackles with reduced breath sounds bilaterally. Peripheral edema was noted. Her oxygen saturation on room air 78%, blood pressure was 200/120 mmHg, pulse rate 137 beats/min, respiratory rate was 40 breaths/min and body temperature was normal. Electrocardiography showed sinus tachycardia and chest radiography revealed cardiomegaly with pulmonary congestion sign (Fig. 1), compatible with acute pulmonary edema.

Address for Correspondance : dr. Yohanes Susanto
Email : yohanessusantomd@gmail.com

HOW TO CITE THIS ARTICLE :

**ACUTE POSTPARTUM PULMONARY EDEMA
IN A 34-YEAR-OLD
PREECLAMPSIA WOMAN**

Introduction

Postpartum pulmonary edema is a rare clinical entity.¹ Acute pulmonary edema, which signifies severe disease, is a leading cause of death in women with preeclampsia, and the fourth most common form of maternal morbidity. It is also frequently the reason for intensive care admission, and may occur during antenatal, intrapartum or postpartum periods.² Pulmonary edema complicates around 0,05% of low-risk pregnancies but may develop in up to 2,9% of pregnancies complicated by preeclampsia³⁻⁴, with 70% of cases occurring after birth.²⁻³ A clinician needs to be aware of the physiologic changes in the maternal cardiovascular system that accompany pregnancy predispose to the development of pulmonary edema, such as increase in plasma blood volume, cardiac output, heart rate, and capillary permeability and a decrease in plasma colloid osmotic pressure. Resuscitation is the foremost priority, followed by formulation of a differential diagnosis to address the underlying condition.⁴ Here we report a postpartum patient who presented with acute pulmonary edema with severe respiratory compromise.

Case Illustration

The patient was a 34-year-old primigravida woman with preeclampsia who was admitted to the hospital for delivery by cesarean section. Apparently there were no problems with the operative procedure. Approximately 20 hours later, she presented progressive dyspnea. She looked pale, unwell and was able to speak only a few words. On physical examination, she had marked respiratory distress and chest auscultation revealed basal crackles with reduced breath sounds bilaterally. Peripheral edema was noted. Her

oxygen saturation on room air 78%, blood pressure was 200/120 mmHg, pulse rate 137 beats/min, respiratory rate was 40 breaths/min and body temperature was normal. Electrocardiography showed sinus tachycardia and chest radiography revealed cardiomegaly with pulmonary congestion sign (Fig. 1), compatible with acute pulmonary edema.

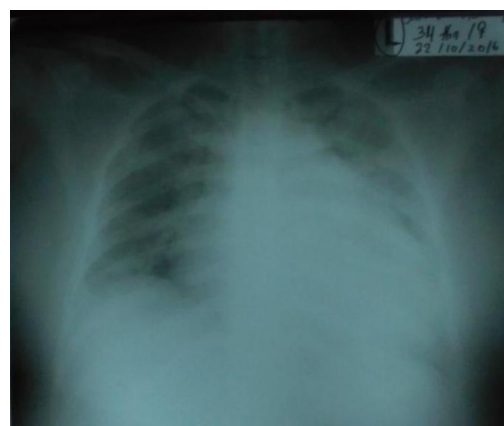


Fig. 1 Chest radiograph showing cardiomegaly with pulmonary congestion sign, compatible with acute pulmonary edema

Laboratory data showed mild leukocytosis ($13.600/\text{mm}^3$), thrombocytopenia ($100.000/\text{mm}^3$), elevated liver function test (AST 62 U/L, ALT 35 U/L), elevated renal function test (BUN 29,87 mg/dL, creatinine 1,5 mg/dL), and hypoalbuminemia (2,3 g/dL). Initial resuscitative measures included oxygen administration by non-rebreathing mask and intravenous diuretics were given but clinical condition of the patient was not improved. Then she was shifted to ICU for respiratory support. The day after, her pulmonary edema was significantly resolved. Oxygen saturation was 98% on room air and ECG was within normal limit. She was hemodynamically stable and was

weaned off the ventilator. Seven days later she was discharged with medications which included antibiotic, diuretic and anti hypertensive agent

Discussion

The differential diagnosis for postpartum dyspnea without pulmonary edema include pulmonary embolism, amniotic fluid embolism, pneumonia, foreign body aspiration and psychogenic dyspnea. These diagnosis were promptly excluded in this case by history, physical examination, and noninvasive data. Dyspnea with pulmonary edema includes cardiogenic and non-cardiogenic causes. Cardiogenic causes are peripartum cardiomyopathy, preeclampsia related with heart failure, underlying cardiac disease (e.g. valvulopathy), myocardial ischemia and sepsis with poor cardiac output. Non-cardiogenic causes are iatrogenic fluid overload, thyroid disease, tocolytic therapy or medication-related sepsis and acute respiratory distress syndrome.^{1,5}

Pulmonary embolism would not account for diffuse rales, a congested chest x-ray film, high wedge pressure and diffusely hypokinetic LV function on echocardiography. Amniotic fluid embolism is a rare but potentially fatal outcome of pregnancy.⁶ The classic presentation involves the acute onset of severe dyspnea, hypoxemia and hypotension, followed within minutes by cardiac arrest. It usually occurs during labor and delivery. The patient typically has a sudden deterioration in her condition and may have cardiac arrest.⁵

Iatrogenic fluid overload is recognized as a significant risk factor for the development of acute pulmonary edema. Historically, the use of intravenous fluids was thought to improve maternal cardiovascular

parameters; however, in one large trial and a systematic review, volume expansion was not beneficial. Intravenous fluid therapy may also exacerbate acute respiratory distress syndrome, leading to hypoxemia, high airway pressures and difficulty with ventilation. The postpartum period is high-risk for the development of acute pulmonary edema. The use of intravenous fluids to increase plasma volume or treat oliguria, which is multifactorial in nature, in a woman with normal renal function and stable serum creatinine levels, is therefore not recommended. Antenatal fluid therapy may be indicated if there are concerns about placental perfusion; however, communication with the obstetric team and cautious use should occur, with close monitoring of cardiovascular and respiratory function.²

Tocolytic agents, which include terbutaline, ritodrine, salbutamol, and isoxsuprine, suppress premature uterine contractions during pregnancy. These B-adrenergic agonists increase intracellular cyclic adenosine monophosphate levels, thus decreasing muscular contraction. Pulmonary edema has been reported in association with the short-term use of B-adrenergic agonists (average 54 hours) in late pregnancy with an incidence of approximately 0 to 4,4%. Pulmonary edema occurs during current or recent (<24 hours) usage or appears less than 12 hours postpartum when tocolytic therapy has failed. Unlike pulmonary edema due to congestive heart failure, cardiomegaly and pulmonary vascular redistribution are generally absent in cases that are drug-related.¹⁻²

Peripartum cardiomyopathy (PPCM) is a rare life-threatening cardiomyopathy of unknown cause that occurs in the peripartum period in previously healthy women. Typically, it can occur in the last month of pregnancy or in the 5 months

following delivery. Common reported risk factors for PPCM are advanced maternal age, multiparity, multiple gestations, African American race, obesity, malnutrition, gestational hypertension, preeclampsia, diabetes, poor prenatal care, breast-feeding, cesarean delivery, substance and tobacco abuse, prolonged tocolysis, and family history. Symptoms of PPCM are identical to those of congestive heart failure and include fatigue, paroxysmal nocturnal dyspnea, pulmonary edema, pedal edema, and distended neck veins. Symptoms such as fatigue, dyspnea, and edema are often present in late pregnancy, making it difficult to identify patients with PPCM.⁷⁻⁸ Additionally, preeclamptic parturients may manifest symptoms of respiratory distress due to capillary weak. Ultimately, PPCM remains a diagnosis of exclusion. Other causes of cardiomyopathy must be excluded prior to accepting a diagnosis of PPCM.⁷ Because of the poorly understood nature of this disease, the diagnosis is primarily established on clinical grounds, and laboratory testing remains basically nonspecific.⁶ Current diagnosis of PPCM is based on the presence of 4 clinical criteria: (1) the development of cardiac failure within the last month of pregnancy or within 5 months of delivery, (2) the absence of another cause to which the cardiac failure can be attributed, (3) no signs or symptoms of heart disease prior to the last month of pregnancy, and (4) a left ventricle ejection fraction of less than 45%.^{1,7-8}

Preeclampsia is a multisystem major cardiovascular disease of pregnancy with hypertension as its main clinical manifestation.²⁻³ Pulmonary edema complicates around 0,05% of low-risk pregnancies but may develop in up to 2,9% of pregnancies complicated by preeclampsia.³⁻⁴ Acute pulmonary edema, which signifies

severe disease, is a leading cause of death in women with preeclampsia,^{2-4,9} and the fourth most common form of maternal morbidity.² It is also frequently the reason for intensive care admission.^{2-3,9}

The causes of pulmonary edema are often multifactorial.^{1-4,10} According to the Starling equation, any factor that results in a reduction in colloid osmotic pressure (or in the colloid osmotic pressure/pulmonary capillary wedge pressure gradient), an increased in capillary permeability or an increase in intravascular hydrostatic pressure will lead to extravasation of fluid from the vasculature and predispose to the development of pulmonary edema.³⁻⁴

The underlying physiologic changes in the maternal cardiovascular system that accompany pregnancy predispose to the development of pulmonary edema. Such changes include an increase in plasma blood volume, cardiac output, heart rate, and capillary permeability and a decrease in plasma colloid osmotic pressure. These changes are often exaggerated in the setting of preeclampsia, leading to a further increase in the incidence of pulmonary edema.⁴ Labor is associated with further increases in cardiac output (15% in the first stage and 50% in the second stage). Uterine contractions lead to an auto-transfusion of 300-500 ml of blood back into the circulation and the sympathetic response to pain and anxiety further elevate the heart rate and blood pressure. Cardiac output is increased between contractions but more during contractions. Following delivery there is an immediate rise in cardiac output due to relief of the inferior vena cava obstruction and contraction of the uterus, which empties blood into the systemic circulation. Cardiac output increases by 60-80% followed by a rapid decline to pre-labor values within about one

hour of delivery. Transfer of fluid from the extravascular space increases venous return and stroke volume further. Those women with cardiovascular compromise are therefore most at risk of pulmonary edema during the second stage of labor and the immediate postpartum period. Cardiac output has nearly returned to normal (pre-pregnancy values) two weeks after delivery, although some pathological changes (e.g. hypertension in preeclampsia) may take much longer.¹¹ Moreover, in normal pregnancy, plasma colloid osmotic pressure decreases from around 22 mmHg at term to 16 mmHg after delivery (and from 18 mmHg at term to 14 mmHg postpartum in pregnancies complicated by preeclampsia). The reduction in colloid osmotic pressure after delivery may result from excessive blood loss, fluid shifts secondary to increased capillary permeability (especially in preeclamptic pregnancies), or excessive crystalloid infusion. Such changes help to explain at least in part why 70-80% of pulmonary edema in the setting of preeclampsia develop after delivery.⁴ An additional feature that may predispose to the development of pulmonary edema in the setting of preeclampsia is an increase in capillary leak and capillary fluid extravasation secondary to vascular endothelial damage.³⁻⁴

The occurrence of acute pulmonary edema in a hypertensive pregnant or recently pregnant woman is a medical emergency and should trigger an emergency response aimed at rapidly assembling an experienced team of staff. Further deterioration may occur, leading to cardiac arrest, and staff should be prepared to institute advanced life support and consider peri-mortem caesarean section. Transthoracic echocardiography can assist in

differentiating a low cardiac output from a high cardiac output state, as well as exclude other important causes of acute pulmonary edema.²⁻³

Despite the risks of aspiration, non-invasive ventilation should be tried as the initial technique before tracheal intubation, as it provides increased inspired oxygen concentration, displaces fluid from the alveoli into the pulmonary and subsequently systemic circulation, decreases the work of breathing, and decreased the need for tracheal intubation. The use of non-invasive ventilation also avoid the complications associated with tracheal intubation in pregnant or recently pregnant women who are hypertensive, such as intracerebral haemorrhage. Mechanical ventilation strategies incorporating the known cardiorespiratory and metabolic changes of pregnancy need to be considered when ventilating the lung of a pregnant or recently pregnant woman, as well as the lung protective strategies of low tidal volumes and low peak pressures. Avoidance of aortocaval compression is essential.²⁻³

Urgent reduction of critically high blood pressure with an intravenous antihypertensive agent is necessary. Nitroglycerin (glyceryl trinitrate) is recommended as the drug of choice in preeclampsia associated with pulmonary edema. An alternative agent, sodium nitroprusside, is recommended in severe heart failure and critical hypertension; however it should be used only with caution and by experienced clinicians. Intravenous furosemide is used to promote venodilation and diuresis. If hypertension persists despite the combination of nitroglycerin or sodium nitroprusside and furosemide, then a calcium channel antagonist such as nicardipine or nifedipine may be considered. Prazosin as well as

hydralazine may also be considered; however, reflex tachycardia may be deleterious in this setting. Intravenous morphine may also be given as a venodilator and anxiolytic. High dependency care and close observation are essential.²⁻³

Women who suffer from preeclampsia and experience acute pulmonary edema are at increased risk of cardiovascular complications in later life, including hypertension, ischemic heart disease, stroke and renal disease. They should be closely monitored with control of blood pressure until resolution of the initial disease process and then followed up regularly, with observation for the long-term complications of the disease. Angiotensin-converting enzymes, while contraindicated in pregnancy, are safe to use in the postpartum period. Risk reduction strategies should be offered, such as weight reduction and smoking cessation programs, dietary modification, encouragement of regular exercise and control of hypertension. In women who require long-term treatment, the aims are to modify the underlying cardiac function or structural pathology.²⁻³

Conclusion

Acute pulmonary edema is an indicator of significant morbidity and may lead to mortality in pregnant women. Future work needs to focus on the implementations of simplified algorithms for critically ill pregnant women, applicable across all disciplines, concentrating on the importance of clinical symptoms and signs. Finally, the use of transthoracic echocardiography should be encouraged both as an educational tool and to aid diagnosis and management. Acute pulmonary edema in a previously healthy woman who has

recently given birth is an uncommon clinical scenario with some life-threatening complications. A multidisciplinary team that includes anesthesia provider, obstetricians, internist, cardiologist and critical care specialists will be needed to help aid in the diagnosis and management. No matter what the underlying pathology, prompt appropriate resuscitation is always the first priority.

References

1. Ho MP, Cheung WK, Tsai KC. Acute Postpartum Pulmonary Edema: A Case Report. *J Emerg Crit Care Med.* Vol. 21, No. 3, 2010;157-160.
2. Dennis AT, Soldordal CB. Acute Pulmonary Oedema in Pregnant Women. *Anaesthesia* 2012;67:646-659.
3. Devi DS, Kumar BJ. A Case of Severe Preeclampsia Presenting as Acute Pulmonary Edema. *Int J Reprod Contracept Obstet Gynecol.* 2016;5:899-902.
4. Norwitz ER, et al. Acute Complications of Preeclampsia. *Clinical Obstetrics and Gynecology.* Lippincott Williams & Wilkins, 2002; Vol 45(2):308-329.
5. Masuda IK, Nasir UA, Md.Shahabuddin K. Acute postpartum Pulmonary Edema in a 32-Year-Old Woman Five Days after Cesarean Delivery. *J Enam Med Col* 2013; 3(2):113-116.
6. Tavel ME. A Problem of Pulmonary Edema Developing Postpartum. *Chest* 1994; 106:1883-1884.
7. Cunningham LC et al. Severe Preeclampsia, Pulmonary Edema and Peripartum Cardiomyopathy in a Primigravida Patient. *AANA Journal*, 2011; Vol 79(3):249-255

8. Mishra VN et al. Peripartum Cardiomyopathy. JAPI, 2013; Vol 61:268-273
9. Charlene ET et al. Acute Pulmonary Oedema as a Complication of Hypertension During Pregnancy. Informa Healthcare. 2009, Early Online 1-13.
10. N. Arulkumaran et al. Severe Pre-eclampsia and Hypertensive Crises. Best Practices and Research Clinical Obstetrics and Gynaecology. El Sevier 2013; 27:877-884
11. Priya SP et al. Physiological Changes in Pregnancy. Cardiovasc J Afr. 2016 Mar-Apr; 27(2):89-94.